

Vision and care of the eyes



Eye problems which may occur in PWS

The chromosome abnormality that causes Prader-Willi syndrome leads to various problems in development, including a number of ocular features.

Squint (Strabismus)

Perhaps 3% of the general population have a squint (strabismus), but it occurs much more frequently in congenital conditions that involve chromosome abnormality.

The squint might be constant or, less commonly, intermittent. One eye may consistently be the straight one, or the eye which is the straight one may swap from one to the other (alternating).

About 60% of children with Prader-Willi syndrome have a squint, which is present at birth or occurs soon after. Almost all squints in PWS are of the crossed-eyes type (esotropia). When one eye looks straight ahead, the other eye turns inward towards the nose.

Wall eyes (exotropia), in which the eye not looking straight ahead turns outward away from the nose, is much less common as an original fault in PWS. However, it is a feature in some teenagers and adults as a later result of the surgical correction of crossed-eyes due to 'post-operative drift'.

The development of a squint at an early age in PWS could be due to the hypotonia (weak muscle tone) present at birth.

Another factor could be a restriction of eye muscle movement caused by the reduced space available in the eye socket, which is associated with the narrow face and almond shaped eyes seen in many people with PWS.

Need for early treatment of a squint

The effects of a squint are not merely cosmetic. During infancy, the visual system is rapidly developing and straight eyes are necessary for normal visual development.

If the eyes are not both directed at exactly the same point, then two different images will arise, sending confusing information to the processing centres in the brain. This will result in adaptations in the visual system rapidly occurring in order to overcome the confusion.



Treatment of squint (strabismus)

In some cases where the squint is associated with appreciable long sightedness, or unequal focussing in the two eyes, it is possible that the squint could be treated by spectacle correction alone. It is not necessary for children to be able to read for a full eye examination to be carried out.

Although wearing spectacles at a very young age might be problematical for some children with PWS, it is worth making an effort to keep them on as much as possible. The aim of spectacles will be to equalise the vision in the two eyes and to keep the two eyes straight to allow full visual development.

In perhaps a majority of children with an early developing a squint, spectacles alone will not be sufficient and a surgical operation will be necessary to straighten the eyes. This is best carried out an early stage to give the best chance for the development of normal two-eyed (binocular) vision.

Three-dimensional vision (stereopsis)

Accurate three-dimensional vision (stereopsis) develops at around four to six months of age. If the eyes are not straight during this period, good stereopsis will not develop.

The angle or degree of a squint may be quite small in some children so that it is not noticeable in normal circumstances. T

here are many competing health and welfare concerns for parents of children with PWS, but the eyes should be examined as soon as possible, preferably by the age of four months, to enable the best chance for the development of good two-eyed (binocular) vision.

Amblyopia

Firstly, one eye becomes the dominant sighting eye and the image from the other eye is switched off (suppressed). If one eye is consistently suppressed then the necessary visual pathways (rather like electrical circuits), leading from the image-receiving retina in the eye to the appropriate areas in the brain, will not be formed properly.



The sharpness of vision (visual acuity) cannot then develop properly and a lazy eye (amblyopia) will be the inevitable consequence. This is present in about 40% of people with PWS.

It may be necessary to put a patch over the better eye (occlusion therapy) for a time, to prevent suppression and to encourage the vision in the weaker eye to develop. Occlusion therapy needs to be carried out during the visual development period, before the age of about 5 years. After this time it is much less effective.

Refractive error (hyperopia, myopia, astigmatism)


Long-sightedness (Hyperopia)

In long-sightedness, vision is often good, particularly for far distance, but some natural accommodation usually occurs to correct the hyperopia, keeping vision clear.

Almost all children with PWS are long-sighted to a greater or lesser extent. A low degree of long-sightedness, relatively equal in the two eyes, is normal in infancy and childhood.

However, if the degree of long-sightedness is quite different in the two eyes or is of large magnitude, the increased accommodation required, in keeping vision clear, can only occur along with increased convergence of the eyes.

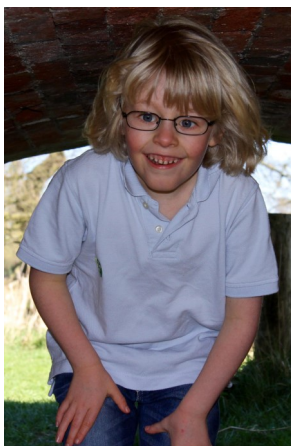This will increase the possibility of squint and amblyopia developing and spectacles will be required to correct it.

 **Almost all children with PWS are long-sighted to a greater or lesser extent.**

Short-sightedness (Myopia)

In short-sightedness (myopia), near vision is good but far vision is blurred.

Trying to use the power of accommodation to correct the short-sightedness only makes the vision more blurred and so, unlike long-sightedness, it cannot be corrected temporarily by natural means.



Astigmatism

Astigmatism means that the lens of the eye does not have a perfectly spherical surface.

The curvature is greater along one meridian than along the opposite meridian - a so-called toroidal surface. To help imagine this, a soccer ball has a spherical surface and a rugby ball has a toroidal surface.

Astigmatism is commonly associated with both long and short-sightedness.

A correction for any astigmatism present is usually incorporated in the prescribed spectacle correction. People with PWS are often found to have significant degrees of astigmatism.

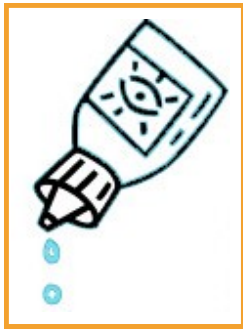Frequency of eye examinations

The earlier in the life of a child with PWS that potential eye problems are detected, the easier the management will be and the more successful the likely outcome.

If an appointment has not been arranged by your paediatrician or child development centre, you can refer your child yourself to see an ophthalmologist - this is usually done via an optician.

During the period that an eye condition is being treated, the practitioner who is looking after the eyes will give advice on frequency of review.

Otherwise children should be seen annually



Conjunctivitis and blepharitis

External eye conditions - conjunctivitis and blepharitis - are common in children and adults with PWS. These conditions are often only temporary but sometimes treatment is necessary. Blepharitis can be very persistent.

Conjunctivitis

The white of our eyes (sclera) is covered by a thin transparent membrane, the conjunctiva, which at the top, bottom and sides of the eyeball continues back as the lining of the eyelids.

Tiny blood vessels thread through the membrane, but they are so small that they are not usually obvious. The conjunctiva is sensitive to allergy and infection and, when this occurs, the little blood vessels become more prominent, making the eye appear red (conjunctivitis or 'pink eye').

If the eyes are also itchy, the problem is usually allergic in origin. This might be due to hay fever or perhaps to something rubbed into the eyes from hands or fingers.

A more prickly sensation usually means infection, and if this lasts for more than a day or two, particularly if accompanied by a discharge, a visit to the optometrist or GP is indicated.

If crusty deposits are present on the eyelashes, these need to be removed. A fresh piece of gauze dipped in a dilute solution of baby shampoo (1 part shampoo to 5 parts water), using cooled water that has been previously boiled, can be rubbed along the edges of the eyelids.

Alternatively, ready-made eyelid cleaners - tissue squares impregnated with a suitably formulated solution, are commercially available. This will usually be sufficient treatment to keep the condition at bay. If it is severe or persistent, antibiotic eye drops and/or oral antibiotic medication are sometimes necessary.

Blepharitis

Inflammation of the eyelids, usually around the lid margin (edge) and eyelashes, ranging from very mild to severe, is referred to as blepharitis. It is fairly common and can be due to a generalised skin condition (seborrhoeic blepharitis) or due to a low-grade bacterial infection (staphylococcal blepharitis).

It is not contagious and cannot be passed from person to person.

Signs and symptoms include yellow or white flakes or scales crusted around the eyelashes, especially on waking, redness of the lid margins, a scratchy feeling and watering. It can be diagnosed by viewing the eyelids through a slit-lamp bio microscope, an instrument found in the majority of optometrists' practices.

Abnormalities in the function of tiny oil glands in the lids may be a contributory cause to the development of blepharitis and lack of hygiene and eye rubbing can result in alterations to the bacterial colonies that normally live on the skin.

Pale coloured eyes and the effect of light

Many children with PWS have blonde hair and pale blue eyes. These children are likely to have a reduced amount of pigment within the coloured part of the eye (iris) and also in the light-sensitive membrane inside the eye (retina).



Because of the reduced amount of pigment, up to 25% of children with PWS will exhibit iris translucency, detected with the slit-lamp bio microscope. When the light beam of the instrument is shone through the pupil and the beam reflected back from the retina is observed through the microscope, a glow of light can be seen not only in the pupil but also passing through the fibres of the iris, which would normally be opaque to light.



This means that more light than usual is entering the eyes, indoors and outside. This is unlikely to cause any problems indoors, but this may not be the case when outside in the sunlight.

The lens of a child's eye absorbs less ultra-violet than in adulthood, so more of these short wavelengths of light are able to pass through to the retina.

For these children sunlight outside might be rather dazzling but, more importantly, in the long term, the passage of excessive amounts of ultra-violet light into the eye could be considered to be a potential hazard.

The use of a peaked cap is an easy way to reduce the amount of the sun's rays directly entering the eyes. Wearing sun spectacles outdoors with a tint to eliminate the ultra-violet light and reduce blue light would also be a sensible precaution.



**Thank
you**

**Many thanks to
Peter Warren
MSc. ClinOptom
FC Optom for
contributing this
article.**

Vision and care of the eyes

PWSA UK

**Suite 4.4 ,
Litchurch Plaza
Litchurch Lane
Derby DE24 8AA**

T: 01332 365676

**E:
admin@pwsa.co.uk**

**W:
www.pwsa.co.uk**

**Reg Charity No:
1155846**

© PWSA UK

